

VARIATION IN SIZE AND SHAPE OF A NORMAL ADULT FEMALE PITUITARY GLAND: A RADIOLOGICAL STUDYS. C. Sanjay¹, Mouna Subbaramaiah², Jagannatha S. R³**HOW TO CITE THIS ARTICLE:**

S. C. Sanjay, Mouna Subbaramaiah, Jagannatha S. R. "Variation in Size and Shape of a Normal Adult Female Pituitary Gland: a Radiological Study". Journal of Evolution of Medical and Dental Sciences 2014; Vol. 3, Issue 18, May 05; Page: 4934-4939, DOI: 10.14260/jemds/2014/2534

ABSTRACT: The pituitary gland produces several hormones that regulate growth, metabolism and reproduction. Deviations from the normal functions of the gland certainly derange the harmony of life. Normal pituitary gland shows variation in size and shape. There is a recognized need for more normative data on female pituitary size in the Indian population hence the study was done using magnetic resonance instrument regarded as modern tool with less error. It was noted that the gland was more convex/globular in the younger age group but as advanced the superior surface became more concave. The mean height of pituitary gland was 6.27 mm \pm 0.56, mean length was 9.10 mm \pm 0.78 and the mean width was 11.22 mm \pm 0.82. The size of pituitary gland also changed with age. The height decreased significantly as age advanced. The width initially increased up to 40 years and later decreased. The results of the study can be applied to clinical practices particularly when clinical symptomatology of patients with physiologic pituitary hyperplasia can mimic pituitary tumor.

KEYWORDS: pituitary, female, magnetic resonance imaging, adult.

INTRODUCTION: The pituitary gland (hypophysis cerebri) is a reddish grey, ovoid body which lies within the hypophyseal fossa of the sphenoid bone. The gland measures about 12 mm in transverse and 8 mm in antero-posterior diameter and weighs about 500 mg. It is covered superiorly by diaphragma sellae, which is pierced centrally by an aperture for the infundibulum. Structurally the gland is divided into a larger anterior region (adenohypophysis) and smaller posterior region (neurohypophysis).

They differ in structure, development, and their vascular and neural supplies. The gland produces several hormones that regulate growth, metabolism and reproduction. Deviations from the normal functions of the gland certainly derange the harmony of life.¹ Pituitary gland morphology is altered in many situations like Prolactinomas (60%),² somatotrophic adenoma(30%)³ and pituitary adenomas which accounts for 10-15% of all diagnosed intracranial neoplasms.⁴

Normal pituitary gland shows variation in size and shape as evident in some study. The gland tends to be globular in shape at birth and becomes more flattened with age. Previous observers have noted transient changes in the shape or signal intensity of the pituitary gland at different stages of life.⁵ The pituitary height in males was significantly lower than that in females.

These changes reflect the complex hormonal environment of the gland and are most pronounced at times of hormonal flux, such as menarche and pregnancy.⁶ The decline in pituitary height with age may also reflect the process of aging and a physiological pituitary atrophy.⁷ However patients with advanced age had a significantly higher pituitary grade (in shape).⁸

Consequently, there are many occasions in which one encounters such borderline pituitary abnormalities as physiological hypertrophy, microadenoma, inflammatory disease, empty sellae, and so on. There is a recognized need for more normative data on female pituitary size in the Indian

ORIGINAL ARTICLE

population. Magnetic resonance (MR) imaging has proved to be an accurate diagnostic technique for use in examinations of the pituitary gland. MR allows multi-planar scan of better contrast \pm resolution than CT without bony artifacts.⁹ The present study was undertaken to note the variation in size and shape of a normal pituitary gland in females of adult age group.

MATERIALS AND METHODS: The study was carried out in department of Radiology, KIMS Hospital and Research Centre, Bangalore in the outpatient section. Purposeful sample was chosen which included 120 females of adult age group (20 to 60 years) who underwent routine MRI scan for indications other than those related to pituitary gland disorders. Any history related to the pituitary gland or hormonal disorders, pituitary surgeries, treated by exogenous hormonal/steroid/drugs like reserpine, phenothiazine, sulpride therapy, pregnancy and lactation, and gross pathology of the pituitary gland noted during the scan were excluded from the study. Informed consent for the same was taken from patients. The sample was grouped into four categories A (20-29yrs), B (30-39yrs), C (40-49yrs) and D (50-59yrs).

MR Imaging was acquired on a 1.5-T GE Signa HD-XT. The measurement was taken in sagittal and coronal views (Fig-1). The coronal and sagittal views were displayed by using midline plane of both T₁-weighted sagittal spin-echo and T₂- weighted coronal spin-echo image. All images were taken on 4mm thick slice then were constructed on a 512 x 256 matrix. The height from upper to lower, the width from the right to the left and the shape of pituitary gland were studied in true midline views, where the stalk of the pituitary gland, Sylvius' aqueduct and posterior gland bright spot could be visualized. The image was reviewed using the electronic caliper of the display. Shape of the Superior Surface of Pituitary (SS) was recorded as flat, concave, and convex.

The measurements were mean \pm SD in the scale of mm. Data analysis by SPSS, test the relation between mean size height/ width with age groups by One way ANOVA test and found frequency of shape evaluated to percentage, considered the P-value was less than 0.05 refer to a significance.

RESULTS: We observed extremely wide variation in the morphology of the pituitary gland on high resolution MRI regardless of subject age. Results are tabulated in tables and graphs.

No two pituitaries were identical in shape. However they could be broadly grouped into three types namely concave, flat and convex varieties depending on the superior surface. It was noted that the gland was more convex/globular in the younger age group A (20-29) but as advanced the superior surface became more concave. Flat superior surface was seen predominantly in the age group D (30-39) [Table: 1 & Graph: 1].

The mean height of pituitary gland was 6.27 mm \pm 0.56, the mean length was 9.10 mm \pm 0.78 and mean width was 11.22 mm \pm 0.82. The size of pituitary gland also changed with age. The height decreased significantly as age advanced. However there was a mild increase in the height noted in the age group C (40-49). The length initially increased up to 40 years and later decreased. Maximum width was noted in the third decade and older age group. The changes were significant with $p < 0.01$ [Table: 2 & Graph: 2].

DISCUSSION: A change in the shape and size of normal pituitary gland was evident from previous studies. The gland tends to be globular in shape at birth and becomes more flattened with age.⁵

ORIGINAL ARTICLE

Patients with advanced age had a significantly higher pituitary grade (in shape).⁸ Results of the present study correlated with previous studies. It was noted that the gland was more convex/globular in the younger age group A (20-29). Flat superior surface was seen predominantly in the age group D (30-39.) As age advanced further the superior surface became more concave. The decline in pituitary height with age may reflect the process of aging and a physiological pituitary atrophy.⁷

Previous observers have noted transient changes in the shape or signal intensity of the pituitary gland at different stages of life, which also reflect concurrent changing of hormonal levels⁵. These changes reflect the complex hormonal environment of the gland and are most pronounced at times of hormonal flux, such as menarche and pregnancy.⁶

Hayakawa et al., while working on a cohort of Japanese population reported a peak in the height of the gland in 10-15 years old age group.¹⁰ Increased secretion of LH and FSH is the main cause of increased height of the gland at puberty. Levels of both hormones are high in this age group.

This initial finding was followed by a detailed study by Elester et al. who reported it in 10-20 years old age group.¹¹

On the contrary, Tsunoda et al and Kato et al reported the maximum height of the gland in the third decade of life.^{12, 13} In the present study which was done in age groups 20-60, it was noted that the height of the gland decreased significantly as age advanced, however there was a mild increase in the height noted in the age group C (40-49) concurrent with those of Tsunoda et al. and Kato et al. Pre-menopausal variation in hormonal levels could be the reason for the same. The mean height of pituitary gland in adult females in the present study was 6.27 ± 0.56 mm. Previous authors have noted significant variations from 5.2mm to 9.7mm.^{14, 15} The differences in values may be attributed to racial differences.

The mean length of the gland in the present study was $9.20\text{mm} \pm 78$. Maximum length was seen in the third decade. Thereafter there was a significant decrease in ($p < 0.01$). The mean width of the gland was $11.22 \text{ mm} \pm 0.82$. Maximum width was noted in the third decade showed a mild decrease and thereafter increased in older age group. The values were concurrent with previous studies.¹⁶

This study is an insight to pituitary morphology, at update from the previous research, using MR instrument regarded as modern tool with less error than direct manual. Our information can benefit the clinicians effectively in evaluation of pituitary disease in adult females of Indian population.

CONCLUSIONS: This study gives the database of pituitary morphology and morphometry in adult Indian female population people acquired from MR Imaging. It can be applied to clinical practices particularly when clinical symptomatology of patients with physiologic pituitary hyperplasia can mimic pituitary tumor.

REFERENCES:

1. Crossman AR. ed. Neuroanatomy. In: Standring S, Ellis H, Heally JC, Johnson D, Williams A, Collins P, et al. eds. Gray's Anatomy: The anatomical basis of clinical practice. 39th ed. Edinburgh: Elsevier Churchill Livingstone; 2005. 380-83.
2. Aron DC, Findling JW, Tyrrell JB. eds. Hypothalamus and pituitary gland. In: Greenspan FS, Gardner DG. Eds. Basic and clinical endocrinology. 7th Ed. New York: McGraw Hill; 2004.106-63.

ORIGINAL ARTICLE

3. Maitra A, Abbas KA. eds. Diseases of the endocrine system. In: Kumar V, Abbas AK, Fausto N. eds. Robbins and Cotran pathologic basis of disease. 7th ed. New Delhi: Saunders; 2004. 1156-64.
4. Hemminki K, Forsti A and Ji j. Incidence and Familial risks in pituitary adenoma and associated tumors. *Endocrine related cancer*. 2007; 14: 103-09.
5. Dietrich RB, LIs LE, Greensite FS, Pitt D. Normal MR Appearance of the Pituitary Gland in the First 2 Years of Life. *AJNR*. 1995; 16: 1413-19.
6. Wolpert SM, Molitch ME, Goldman JA, Wood JB. Size, Shape and Appearance of the Normal Female Pituitary Gland. *AJR*. 1984; 143: 377-81.
7. Sharafuddin MJ, Luisiri A, Garibaldi LR, Fulk DL, Klein JB et al. MR Imaging Diagnosis of Central Precocious Puberty: Importance of changes in the Shape and Size of the Pituitary Gland. *AJ Roent*. 1994; 162:1167-73.
8. Tien RD, Kucharczyk J, Bessette J, and Middleton M. MR Imaging of the pituitary gland in infants and children: Changes in size, shape and MR signal with growth and development. *AJR*. 1992; 158: 1151-54.
9. Rauschnig W. Sella/suprasellar masses. In: Osborn AG, ed. *Diagnostic Neuroradiology*. St Louis, Mo: Mosby-Year Book; 1994:461-484.
10. Hayakawa K, Konishi Y, Matsuda T, Kuriyama M, Konishi K, Yamashita K, et al. Development and aging of brain midline structures: assessment with MR imaging. *Radiology* 1989; 172:171-7.
11. Elster AD, Chen MY, Williams DW 3rd, Key LL. Pituitary gland: MR imaging of physiologic hypertrophy in adolescence. *Radiology* 1990; 174:681-5.
12. Kato K, Saeki N, Yamaura A. Morphological changes on MR imaging of the normal pituitary gland related to age and sex: main emphasis on pubescent females. *J Clin Neurosci* 2002; 9:53-6
13. Tsunoda A, Okuda O, Sato K. MR height of the pituitary gland as a function of age and sex: especially physiological hypertrophy in adolescence and in climacterium. *AJNR Am J Neuroradiol* 1997; 18:551-4.
14. Chambers EF, Turski PA, LaMasters D, Newton TH. Regions of low density in the contrast-enhanced pituitary gland: normal and pathological processes. *Radiology* 1982;144:109-113.
15. Swartz JD, Russell KB, Basile BA, O'Donnell PC, Popky GL. High resolution computed tomographic appearances of intrasellar contents in women of childbearing age. *Radiology* 1983; 147:115-117.
16. Oon CK, Lavender JP, Joplin GF. The width of the normal pituitary gland: a comparison of two radiological methods of measurement. *Departments of Radiodiagnosis and Medicine*. 1961; 35(414):418-21.

ORIGINAL ARTICLE

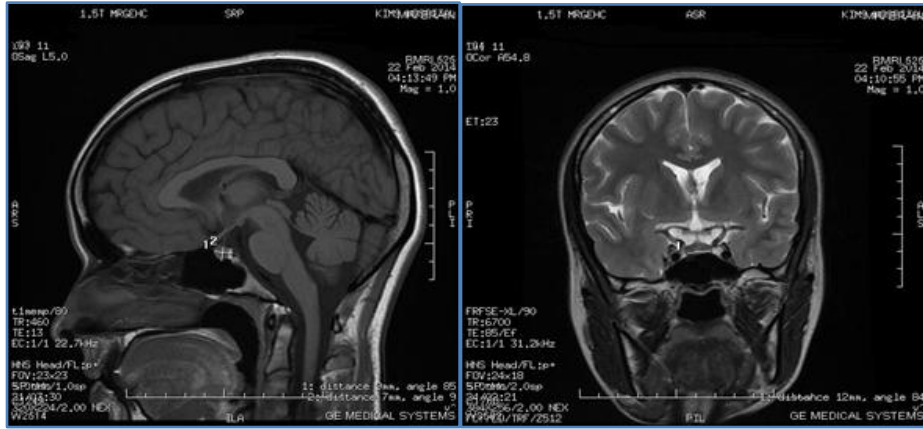
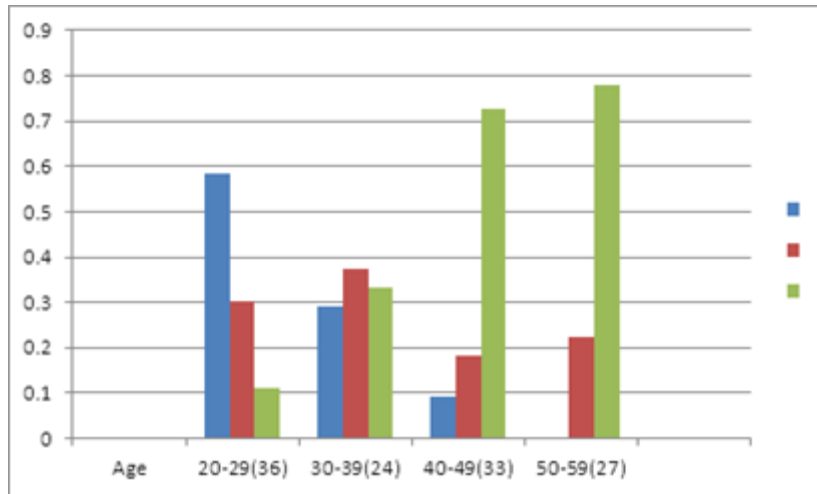
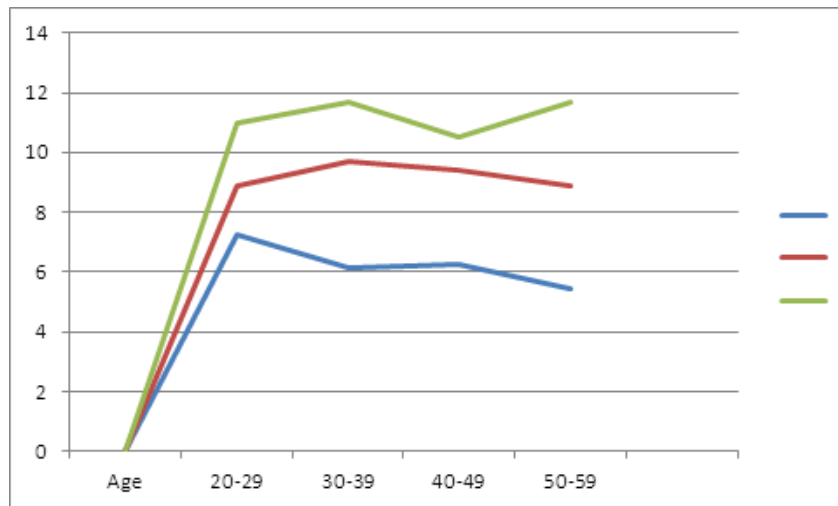


Figure 1: Showing Sagittal and Coronal views of pituitary gland on MRI



Graph 2: Showing height and width of pituitary gland in different age groups



Graph 2: Showing variation of pituitary gland shape in different age groups

ORIGINAL ARTICLE

Age(number)	Convex	Flat	Concave
20-29(36)	58.30%	30.10%	11.10%
30-39(24)	29.20%	37.50%	33.30%
40-49(33)	9.10%	18.20%	72.70%
50-59(27)	0.0%	22.20%	77.80%

TABLE 1: Showing variation of pituitary gland shape in different age groups

P<0.05

Age	Height (mm)	Mean height(mm)	Length (mm)	Mean length(mm)	Width (mm)	MeanWidth (mm)
20-29(36)	7.22±0.38	6.27±0.56	8.87±0.48	9.20±0.78	11.00±0.26	11.22±0.79
30-39(24)	6.16±1.06	P <0.05	9.67±0.98	P<0.01	11.67±0.52	P<0.05
40-49(33)	6.25±0.58		9.38±0.86		10.50±0.38	
50-59(27)	5.43±0.28		8.86±0.56		11.71±1.28	

TABLE 2: Showing height and width of pituitary gland in different age groups

AUTHORS:

1. S. C. Sanjay
2. Mouna Subbaramaiah
3. Jagannatha S. R.

PARTICULARS OF CONTRIBUTORS:

1. Assistant Professor, Department of Anatomy/ Radiology, Kempegowda Institute of Medical Sciences.
2. Assistant Professor, Department Anatomy/ Radiology, Kempegowda Institute of Medical Sciences.
3. Associate Professor, Department Anatomy/ Radiology, Kempegowda Institute of Medical Sciences.

NAME ADDRESS EMAIL ID OF THE CORRESPONDING AUTHOR:

Dr. Mouna Subbaramaiah,
Assistant Professor,
Department of Anatomy,
Kempegowda Institute of Medical Sciences,
Banashankari 2nd Stage,
Bangalore - 560070.
E-mail: mounagowda123@rediffmail.com

Date of Submission: 27/03/2014.
Date of Peer Review: 28/03/2014.
Date of Acceptance: 11/04/2014.
Date of Publishing: 05/05/2014.